

CASE STUDY

Improvement of Migraines in a Child Following Cervical Curve Correction Using the Pierce Results System™

Nate Berner, D.C.¹ & Casen DeMaria, D.C.²

Abstract

Objective: To report the resolution of a cervical kyphosis and an improvement of migraines in a pediatric patient using the Pierce Results System™.

Clinical Features: A 12-year old girl presented with complaints of severe migraines for the last 6 years. Previous chiropractic care had not helped her. The patient suffered from migraines 3x/wk and had missed over 2 months of school due to the pain. Videofluoroscopic examination of the cervical spine revealed a -45cm kyphosis. On cervical flexion, a C1 and C6 lock was noted and upon cervical extension T1 and T2 were locked.

Intervention and Outcomes: Chiropractic care was administered over 6 visits and included thermal scanning, radiographs, videofluoroscopy, toggle set instrument adjusting and pressure adjustments based on the Nimmo-Tonus Technique. The patient demonstrated a significant improvement in her cervical curve upon review of a follow up videofluoroscopic examination and her migraines were resolved.

Conclusion: The patient experienced subjective and objective improvement from the Pierce Results System™ during chiropractic care. Further research is recommended.

Key words: *Pierce Results System,™ vertebral subluxation, chiropractic, pediatric migraine, kyphosis, videofluoroscopy, and thermography*

Introduction

A migraine is a very common and frequent health problem in children and adolescents which has been described as an intolerable pain preventing the child from their daily activities such as going to school or social events.^{1,2} Headaches occur in up to 75% of adolescents and 25% of younger children.³ Prevalence rates range from 3.2% to 10.6% with 10.6% occurring between the ages of 5 and 15 years and 28% in children ages 15-19 years.^{4,5,6} Migraine prevalence is ranked among one of the top 5 health problems of childhood.⁷ This

very common disorder has a serious impact on a child's life and school performance, along with their family and peer relationships. Migraines can result in school absenteeism and lack of involvement in peer activities which can have a long-term effect on a child's health.¹

Headaches and migraines have been commonly underdiagnosed in children and adolescents which may be due to the different presentations that children may have. Neurological symptoms may be more clearly visible than the headache but there may also be other non-headache symptoms associated.⁸ Different from adult migraines, pediatric

1. Private Practice of Chiropractic, Marietta, GA
2. Private Practice of Chiropractic, Cleveland, OH

migraines have a tendency to be bilateral instead of unilateral and tend to be of a shorter duration of time than migraines in adults. Occasionally children have the symptoms that accompany a migraine, which include light sensitivity, nausea, and vomiting without any headache.⁹ To minimize the impact of migraines on a child's quality of life it is important to prevent long-term disability by early recognition and intervention.[†] In addition to the impact on quality of life, migraines weigh heavily on the health care system: a recent study estimated an annual cost of \$11.07 billion in the medical care of insured Americans, which included the costs of care in emergency settings, inpatient care, and the cost of prescription drugs.¹⁰

It has been documented that pediatric patients suffering from migraines undergoing corrective chiropractic care have resolution of their migraine symptoms after the correction of cervical kyphosis.¹¹⁻¹⁵

Diagnosis

Criteria was developed at the International Headache Society in Italy, 2003, to better understand the diagnosis of children and adolescents with headaches. Previous criteria to this time was lacking in sensitivity and specificity. The ICHD-II is the most current foundation for the diagnosis and included a shorter duration, lack of associated symptoms due to the child's inability to describe, as well as a bilateral location versus a unilateral location that is seen with adults.^{1,5,7,9} Migraines are commonly under diagnosed or misdiagnosed in children despite the prevalence.^{1,6,16}

Management

The traditional medical approach of pediatric migraines is the use of non-pharmacologic and pharmacologic measures. This includes Analgesics, Triptans, and other medications for the treatment of acute attacks of migraines and Beta blockers, Calcium channel blockers, anticonvulsants, and antidepressants for the prevention of migraine attacks. The importance of non-medicinal treatment should not be ignored. Behavioral interventions have been used as non-pharmacologic approaches to migraine management which include: treatment protocol, lifestyle habits, and psychological intervention including biofeedback.^{2,4,5,17} Herbal remedies and vitamins such as Feverfew, riboflavin, and coenzyme Q10 have also been suggested for the use of headaches in adults but have not been adequately studied for the prevention of migraines in children.¹⁸⁻²¹

The following is a case report of a 12 year-old child that suffered from pediatric migraines. This case demonstrates the successful outcome of the use of the Pierce Results System™ in the correction of cervical kyphosis as well as the resolution of migraines.

Case Report

History

The patient was a 12-year old female with severe migraines. She began having migraines at 6 years of age. Her family had moved around frequently and had been to previous

chiropractors for 6 years but nothing had helped her with her migraines. The patient at one time had missed over 2 months of school and her teachers were beginning to think that she was "faking it."

The patient suffered from migraines 3x/wk that would last for several hours. Her pain had been getting worse. When asked to rank her pain on a scale of 0 to 10 with 0 being no pain and 10 being the worst pain she had experienced her average pain level was an 8/10, and at its worst the pain was a 10/10. The child suffered from light sensitive migraines as well as having blurry vision when the migraines occurred, and had to lie down when she had a migraine and was unable to do any activity. Sleeping and darkness would also help her migraines. The patient reported no significant past history of illness, injury, family history, or medications.

Examination

Chiropractic examination, thermal scans, videofluoroscopy, and radiographic evaluations were completed following the protocols used in the Pierce Results System™. Using a Tytron™ C-5000 infrared scanner a thermal scan was performed from S2-occiput, and then atlas readings were taken at the left and the right side mastoid fossa. The initial thermal scan had a hyperthermic zone greater than 0.8° C in the cervical region and a hypothermic zone greater than 0.8°C in the thoracic and lumbar regions (Fig 1).

A videofluoroscopic examination revealed changes from the normal +17cm AcuArc measurement ruler. The measurement was a -45cm, indicating the patient had a cervical kyphosis measured on the initial videofluoroscopic evaluation (Fig 4). Lateral cervical radiographs were taken and confirmed the findings from the videofluoroscopic exam. The AcuArc ruler is used in the Pierce Results System™ to measure cervical curve. A normal cervical curve should measure +17cm.

It is known that the cervical spine is supposed to have a normal lordosis.²² Any variation from normal could lead to abnormal biomechanics that is included as a component of the vertebral subluxation complex.²³ A videofluoroscopy examination used for detecting inter-segmental vertebral motion revealed that the patient exhibited abnormal motion patterns on cervical flexion and extension.²⁴ These abnormal motion patterns are a part of the subluxation analysis within the Pierce Results System™.

In cervical flexion the spinous processes should open up and fan out evenly while in extension they should close down on each other. If there is any variation of these motions it is considered "locking" under Pierce protocols indicating subluxation. On cervical flexion, a C1 and C6 lock was noted, and upon cervical extension T1 and T2 were locked. These abnormal motion patterns are part of the kinesiological dysfunction component common to all models of the vertebral subluxation.²⁵

Intervention

The patient was treated for a total of 6 visits over a 1-month time period. The doctor followed the protocols outlined by the Pierce Results System™. These protocols include thermal

scanning for pattern analysis at the beginning of each visit (Fig 1-3). Pattern analysis is applied to the patient's assessment to see how their nervous system responds to chiropractic care.²⁶ Dr. Pierce developed thermal scanning protocols that had specific parameters. The patient should have an average temperature of 93.5°F, the atlas differential should be 0.0°F and the variation bilaterally should be within 1.0°F. The goal of the scan is for it to be changing from visit to visit.²⁷ In order to address the cervical findings of the patient several different adjusting techniques were used including: a high velocity no recoil thrust known as a P-A toggle set, instrument adjusting using the Variable Frequency™ adjusting instrument, and pressure adjustments based on the Nimmo Tonus Technique.¹⁵

In order to address the cervical locks initially, a P-A toggle set was delivered (unlike a toggle recoil the adjustment is held without a recoil after the thrust). The doctor places the inferior hypothenar at the inferior aspect of the spinous process applying a P-A, I-S force into the segment involved activating the drop mechanism on the chiropractic table. This was done on a Zenith model 60 stationary table with a cervical drop headpiece.

On other visits pressure adjustments were done which consisted of a direct pressure contact held on the area of cervical listing. These pressure adjustments last for 30-40 seconds delivered in the same line of drive as an adjustment focusing on removing myofascial trigger points that complicate components of the VSC.¹⁵ Instrument adjusting was used on several visits to assist in removal of cervical flexion and extension locks. An instrument adjuster is a 2 probed hand held instrument that is able to apply a force based on a specific rate, frequency, and preload setting.²⁸

Outcomes

Over the course of the patient's 5 weeks of care she only suffered from 1 minor migraine with a total of 90% improvement of her migraine symptoms. After 5 weeks of care and 6 visits a post fluoroscopic examination was taken in order to document progress. The post videofluoroscopic examination showed a change from the original - 45cm cervical kyphosis to a + 28cm cervical lordosis (Fig 5).

The videofluoroscopic examination also revealed that the lower cervical flexion locks were no longer present. The upper dorsal locks were still present but were an estimated 50% corrected from the original examination and only the C1 cervical flexion lock remained. During each of the child's visits she was scanned (Fig 1-3) and thermal scanning after 5 weeks showed a minor hypothermic zone in the lumbar region.

The patient was no longer exhibiting a thermal pattern based on the Pierce Results protocols, indicating that her nervous system was able to better adapt to her external environment.^{26,27} The post videofluoroscopic, thermal, and subjective changes all showed a significant improvement over the 5 weeks of chiropractic care. The patient remains migraine free as of this writing.

Discussion

Pierce Results System™

The Pierce Results System™ was developed as a system of analysis for the correction of the vertebral subluxation complex. Pierce found that when the components of the VSC were removed normal spinal structure would result. He also determined the main goal of VSC removal was to restore spinal structure and normal spinal intersegmental motion.²⁷ When there is an alteration from normal spinal curvature negative consequences attributed to our health can be present.¹²

Pierce spent 35 years researching what a normal spine should look like. He developed a normal spinal model based on correct structure and motion focusing on detecting the VSC.²⁷ The AcuArc ruler is a tool used in the Pierce Results System™ to measure the curves of the spine. A normal cervical lordosis is measured as +17cm (this measurement represents the radius of an arc). A straight or military neck measures +500cm and a complete cervical reversal known, as a kyphosis measures -17cm. These AcuArc measurements are used in order to determine variations from normal spinal curvature.

Pierce found that the neutral lateral cervical spine follows 6 normal criteria: 1) +17cm curve touching all anterior vertebral bodies from the anterior superior tubercle of C1 to T2 or the lowest visible vertebrae, 2) George's line is a +17cm curve, 3) an atlas angle of 18-24° with atlas being present half way between the inferior aspect of occiput and the C2 spinous process, 4) the inferior C2 vertebral body is parallel with the floor known as a zero degree Whitehorn angle, 5) the zygapophyses angles measuring from 35-55°, 6) all cervical disc spaces being equal height with no osteophytic growth.²⁷ Congenital malformations always needed to be ruled out in order to determine if the patient could achieve normal spinal curvature.^{15,27,28}

The Pierce Results System™ uses several tools for analysis including videofluoroscopy, static radiographs, and thermography. These have been shown in chiropractic literature to have high inter-examiner reliability when detecting components of the VSC including: kinesiopathology, neuropathology, and misalignment.²⁹⁻³¹ The system uses three types of adjusting: a high velocity no recoil force known as a toggle-set, instrument adjusting, and pressure adjustments based on the Nimmo-Tonus Technique.²⁷ These types of adjustments are described in detail by Jaszewski and Galgano.^{15,28} Instrument adjusting and pressure adjustments are used more often than the toggle-set because repeated use of the toggle-set can hinder the progress of VSC correction.²⁷

Chiropractic Management

There is some evidence in the literature to support the chiropractic management of pediatric migraines.^{12,15,32-34} In a case study conducted by Jaszewski and Sorbara following the guidelines of the Pierce "Results System"™ a 7-year old girl showed improvement with idiopathic scoliosis, migraines, attention deficit disorder and vertebral subluxations. This case

provides evidence for the Pierce “Results System”™ resulting in a reduction in migraines in a pediatric patient undergoing chiropractic care.¹⁵

Kelly and Holtz conducted a study on a 12-year-old boy receiving chiropractic care with resolution of vertigo, migraines, and neck pain. They concluded that after one week of chiropractic care the patient had a reduction of his headaches and neck pain and since beginning under chiropractic care he had been regularly attending school with ¼ the absences than the previous year.³²

In a case report by Alcantara and Pankonin an 11-year old male presented with recurrent headaches of a four-year duration. The patient reported a reduction in headaches after four weeks and in the second month of care the patient had a resolution of his headaches completely. Chiropractic care was successful in managing a pediatric patient with migraine-type headaches.³³

There is also some chiropractic literature that shows improvement of headaches in pediatric patients with cervical curve correction. Fedorchuk and Wheeler discuss how restoring the spinal curves to normal result in improved health outcomes. These postural abnormalities result in excessive loading to the spinal structures and cervicogenic headaches may stem from a reduction in lordotic curve or kyphotic curve of the cervical spine. In the case of a 13-year old male following restoration of the cervical curve using chiropractic care there was a positive result in the headaches.¹²

In a case study by Fedorchuk and Cohen on an 8-year old female there was resolution of chronic otitis media, neck pain, headaches, and sinus infection following an increase in cervical curvature and reduction of vertebral subluxation.¹³ In another study conducted by Oakley et al they reported how restoration to a normal cervical lordosis in an 8-year old male had resolved his symptoms of headaches, muscle aches, fatigue, allergies and digestive problems. In Oakley’s article they located only eight documented cases where CBP technique was used to restore cervical lordosis in the pediatric headache population.³⁴ These cases represent cervical curve restoration in pediatric headaches not specifically pediatric migraines.

Conclusion

This is a case study of cervical kyphosis restoration and improvement of migraines using the Pierce Results System™ in a 12-year-old child. Pre and post videofluoroscopic examinations provided objective evidence of cervical curve restoration from the original - 45cm cervical kyphosis to a + 28cm cervical lordosis.

Chiropractic care in this patient was able to increase her quality of life allowing her to not miss school and have a 90% improvement of her symptoms after 6 visits. Further research is necessary to determine how structural correction using the Pierce Results System™ influences pediatric patients suffering from migraines.

References

1. Kabbouche M, Gilman D. Management of migraine in adolescents. *Neuropsychiatr Dis Treat.* 2008 Apr; 4(3): 535-548.
2. Winner P, Rothner A. *Headache in Children and Adolescents.* Hamilton, Ont: BC Decker, Inc; 2001.
3. Bille B. Migraine in school children. *Acta Paediatrica.* 1962; 51(136):16-151.
4. Bakola E, Skapinakis P, Tzoufi M, Damigos D, Mavreas V. Anticonvulsant drugs for pediatric migraine prevention: An evidence-based review. *Eur J Pain.* 2009; 13:893-901.
5. Geraud G, Lanteri-Minet M, Lucas C, Valade D. French Guidelines for the Diagnosis and Management of Migraine in Adults and Children. *Clin Ther.* 2004 No 8; 26:1305-1318.
6. Split W, Neuman W. Epidemiology of migraine among students from randomly selected secondary schools in Lodz. *Headache.* 1999; 39:494-501.
7. Hershey A, Winner P. Pediatric Migraine: Recognition and Treatment. *J Am Osteopath Assoc.* 2005 Apr; 105(2): 2-8.
8. Stewart W, Linet M, Celentano D, Van Natta M, Ziegler D. Age- and sex-specific incidence rates of migraine with and without visual aura. *Am J Epidemiol.* 1991; 134(10): 1111-1120
9. Pakalnis A. New avenues in treatment of paediatric migraine: a review of the literature. *J Fam Pract.* 2001; 18: 101-106
10. Hawkins K, Wang S, Rupnow M. Direct cost burden among insured US employees with migraine. *Headache.* 2008; 48(4): 553-63.
11. Pope M. Applied Chiropractic Biophysics. (chap 12, p.23-24) In: Harrison DD. *Chiropractic: The physics of spinal correction CBP technique.* CBP Seminars, 1994.
12. Fedorchuk C, Wheeler G. Resolution of headaches in a 13 year-old following restoration of cervical curvature utilizing chiropractic biophysics: A case report. *J Pediatr Matern & Fam Health – Chiropr.* Fall 2009(2009:4): Online access 7 p.
13. Fedorchuk C, Cohen A. Resolution of chronic Otitis media, neck pain, headaches & sinus infection in a child following an increase in cervical curvature & reduction of vertebral subluxation. *J Pediatr Matern & Fam Health- Chiropr.* Spr 2009(2009:2): Online access 8 p.
14. Harrison DE, Harrison DD, Hass J. Structural rehabilitation of the cervical spine. Evanston, WY: Harrison CBP® Seminars, Inc.,2002.
15. Jaszewski E, Sorbara A. Improvement in a child with scoliosis, migraines, attention deficit disorder and vertebral subluxations utilizing the pierce chiropractic technique. *J Pediatr Matern & Fam Health – Chiropr* 2010; 2:30-34.
16. Sadovsky R, Dodick D. Identifying migraine in primary care settings. *Am J Med.* 2005; 118(1): 11-17.
17. Shah UH and Kalra V. Review article: pediatric migraine. *Int J Pediatr* 2009; pp.1-7.

18. Yogler Bk, Pittler MH, Ernst E. Feverfew as a preventative treatment for migraine: a systematic review. *Cephalgia* 1998; 18: 704-708.
19. Schoenen J, Jacquy J, Lenaerts M. Effectiveness of high-dose riboflavin in migraine prophylaxis: a randomized controlled trial. *Neurology* 1998; 50:466-470.
20. Rozen TD, Oshinsky MI, Gebeline Ca, Bradley Kc, Young Wb, Schedter Al, et al. Open label trial of coenzyme Q10 as a migraine preventive. *Cephalgia* 2002; 22: 137-141.
21. Arulmozhi DK, Veeranjanyulu A, Bodhankar SL. Migraine: current concepts and emerging therapies. *Vascul Pharmacol* 2005; 43; 176-187
22. Harrison De, et al. A normal spinal position: it's time to accept the evidence. *J Manipulative Physiol Ther* 2000; 23:623-644.
23. Kent c, models of vertebral subluxation: a review. *J Vertebral Subluxation Res* 1996; 1(1): 11-17.
24. Robinson Gk and Lantz C. Videofluoroscopy in chiropractic management of cervical syndromes. *Chiropr* 1991; 93-97.
25. Lantz CA. The vertebral subluxation complex part 2: neuropathological and myopathological components. *Chiropractic Research Journal* 1989; 1(3):23.
26. Stillwagon G and Stillwagon K. Vertebral subluxation correction and its affect on thermographic readings: a description of the advent of the visi-therm as applied to chiropractic patient assessment. *J Vertebral Subluxation Res* 1998; 2(3): 1-4.
27. Pierce WV. RESULTS. Dravosburg, Pa: X-Cellent X-ray Company.
28. Galgano J and Turo D. Correction of cervical kyphosis & health concerns following a single adjustment utilizing the pierce chiropractic technique. *Ann Ver Sub Res* 2011 Jun 9, pp. 37-43.
29. Slusher R, Shook B, Hozjan J, McCauley, Hart J. The reliability of visual x-ray analysis of the cervical spine and pelvis: a preliminary study. *J Vertebral Subluxation Res.* 2010 Mar 25; pp. 1-7.
30. McCoy M, Campbell I, Stone P, Fedorchuk C, Wijayawardana S, et al. Intra-examiner and inter-examiner reproducibility of paraspinal thermography. *PLoS ONE* 2011; 6(2): e16535. doi:10.1371/journal.pone.0016535
31. Antos JC, et al. Interrater reliability of fluoroscopic detection of fixation in the mid-cervical spine. *Chiropractic Technique* 1990; 2(2): 53-55.
32. Kelly DD, Holt K. Resolution of vertigo, migraines and neck pain in a 12-year-old boy receiving chiropractic care-a case study. *J Pediatr Matern & Fam Health-Chirop* 2010 sep 29; 150-153
33. Alcantara J and Pankonin KJ. Chiropractic care of a pediatric patient with migraine-type headaches: a case report and selective review of the literature. *Explore* 2010 Jan/Feb; 6(1); 42-46.
34. Oakley P, Chaney SJ, Chaney TA, Maddox A. Resolution of chronic headaches following reduction of vertebral subluxation in an 8-year-old utilizing chiropractic biophysics technique. *J Pediatr Matern & Fam Health-Chirop* 2011 Aug 11, pp. 82-86.

Figures

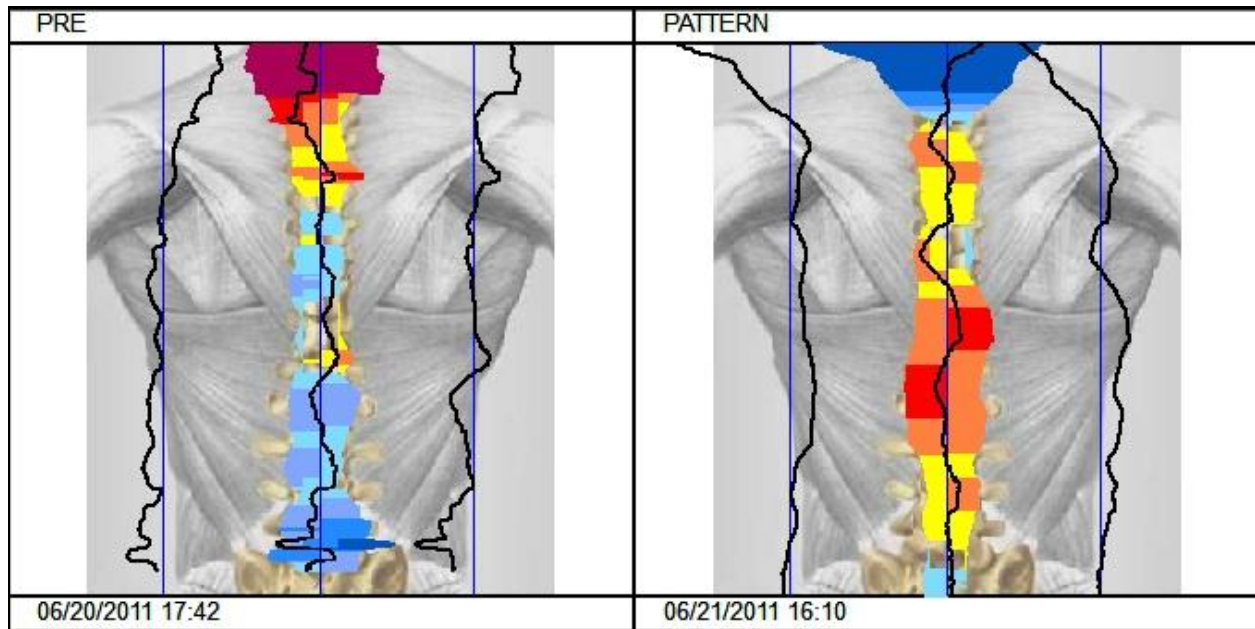


Figure 1. First and second visit thermal scans using Tytron™

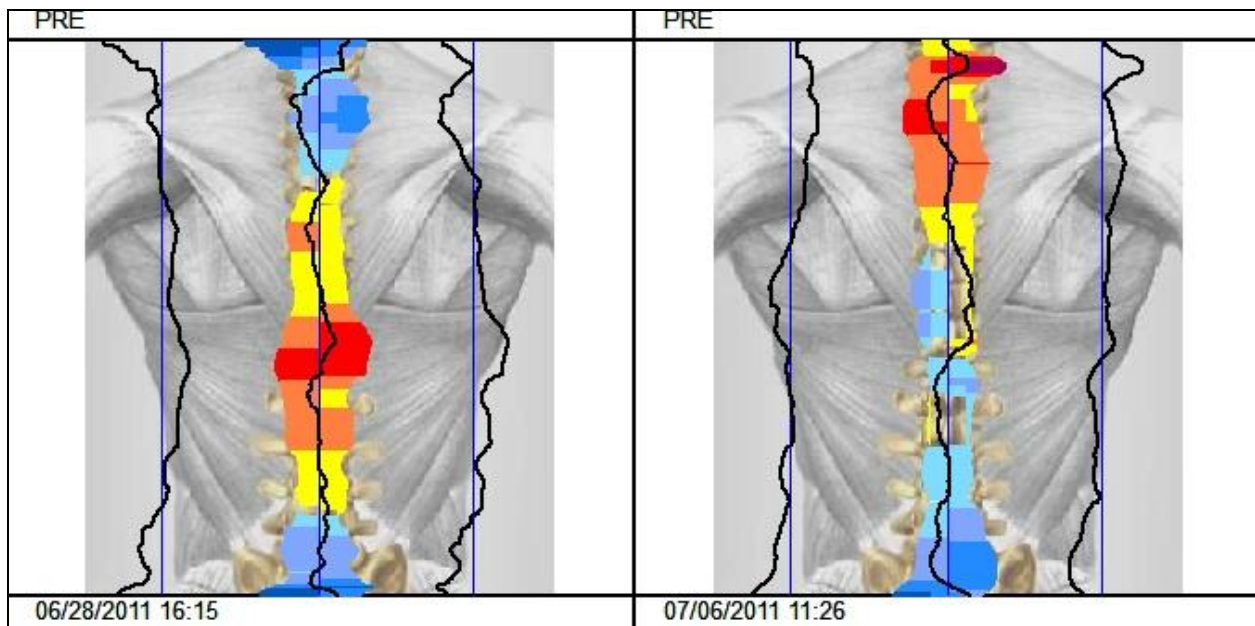


Figure 2. Third and fourth visit thermal scans using Tytron™

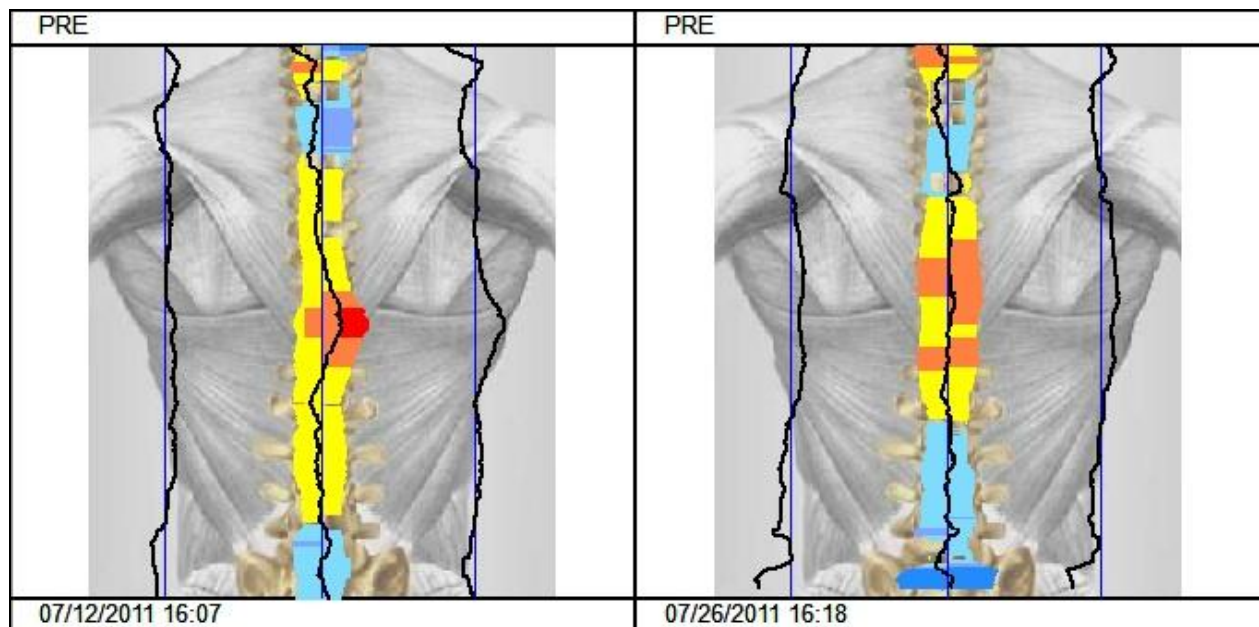


Figure 3. Fifth and sixth visit thermal scans using Titron™

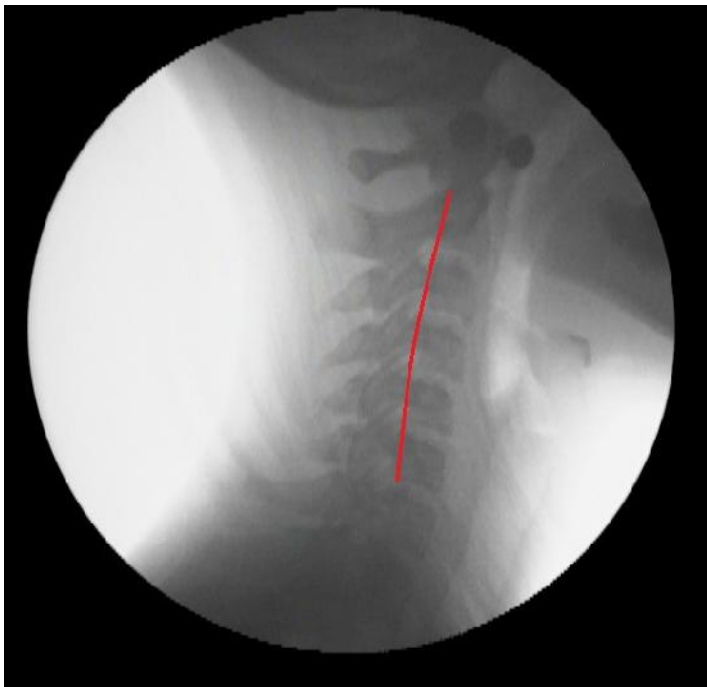

Figure 4. Pre – Lateral cervical under videofluoroscopy

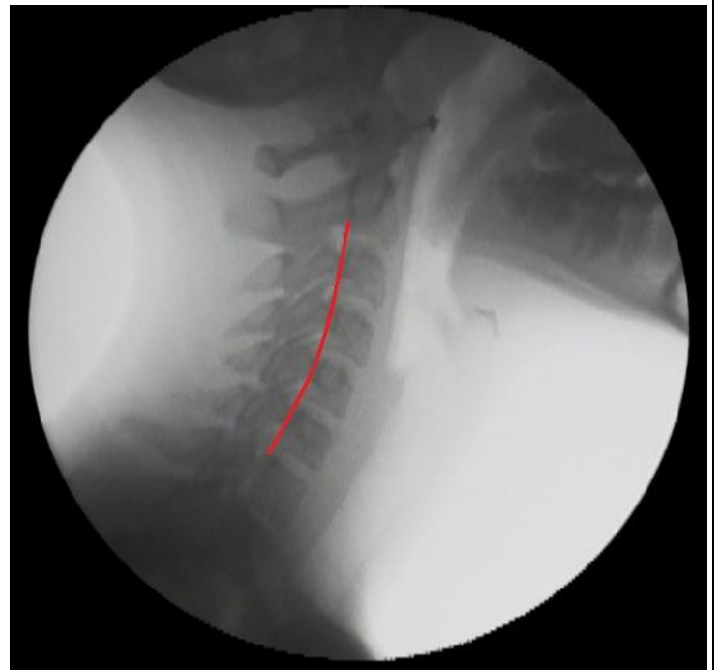

Figure 5. Post – Lateral cervical under videofluoroscopy